Basic A & P II Dr. L. Bacha
Chapter Outline (Martini & Nath 2010)



# Chapt. 22: Digestive System

## 22.1 The digestive system...

- two groups of organs form the digestive system (see Fig. 22-1):

1. digestive tract
   - what is it also called?
   - list the organs that make up the digestive tract:

2. accessory digestive organs
   - list the accessory digestive organs:

## Functions of the Digestive System

- list (and read about!) the six digestive functions:

1. 4.
2. 5.
3. 6.

## The Digestive Organs and the Peritoneum

- the abdominopelvic cavity contains the **peritoneal cavity**, which is lined by a serous membrane called the **peritoneum**:
  - what does the **visceral peritoneum** cover?
  - what does the **parietal peritoneum** line?
  - the serous membranes lining the peritoneal cavity continuously produce what?
    - what is the function of peritoneal fluid?



**Mesenteries** (Fig. 22-2)

- mesenteries suspend organs of the abdominopelvic cavity and attach some organs to others
- mesenteries provide access routes for what?
  - what do they stabilize?
  - what do they prevent?

## Histological Organization of the Digestive Tract (Fig. 22-3)

• the walls of organs of the GI tract from the esophagus to the anal canal have the same 4 basic layers:

eg., small intestine, x.s.

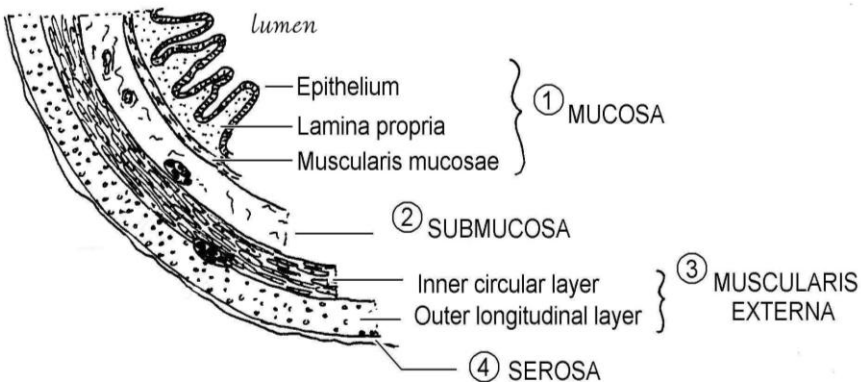


(1) **Mucosa**

- it is mucous membrane that lines the lumen of the GI tract
- there are 3 layers within the mucosa:
  a. **epithelium** - the type varies with the organ
     - contains **enteroendocrine cells**, which secrete what?

  b. **lamina propria** - areolar CT
  c. **muscularis mucosae** – thin layer of smooth muscle

(2) **Submucosa**

- dense CT
- the submucosa contains the **submucosal plexus** (Meissner's nerve plexus) = controls the activity of glands the GI tract and smooth muscle of the muscularis mucosae

(3) **Muscularis Externa**

- skeletal muscle (e.g. mouth, pharynx, part of the esophagus)
  *OR*
  smooth muscle (e.g., part of the esophagus, stomach, intestines)

- arranged in 2 layers (sometimes 3):
  1) inner circular layer
  2) outer longitudinal layer

- the muscularis externa contains **myenteric plexus** (Auerbach's plexus) which controls motility of the GI tract

(4) **Serosa *or* Adventitia**

**SEROSA** ( visceral peritoneum) = a serous membrane of CT covered by a simple squamous epithelium

**ADVENTITIA** = CT only; not covered by an epithelium; the CT blends with that of surrounding structures

## The Movement of Digestive Materials

### PERISTALSIS

- does peristalsis propel materials in one directions?
- peristalsis consists of what?
- describe the activity of the circular and longitudinal muscles during a peristaltic movement and observe Fig. 22-4:

### SEGMENTATION

- segmentation is cycles of localized mixing contractions that occur in what organs?
- function: churn and fragment the bolus, and mix the contents with intestinal secretions
- does segmentation push the contents of the intestines along in one direction?

## 22.2 The oral cavity...

- the **mouth** opens into the **oral** (buccal) **cavity**
- list the four functions of the oral cavity:
- what forms the roof of the oral cavity?
- what dominates the floor of the oral cavity?
- what is the **uvula**?

## The Tongue

• list the four primary functions of the tongue:

• define **lingual frenulum:**

• small lingual glands below the epithelium of the tongue produce secretions that contain water, mucus, and the enzyme **lingual lipase**, which digests lipids

• **extrinsic muscles** of the tongue
- are skeletal muscles that originate on bones of the skull or the soft palate and insert onto the tongue
- they alter the position of the tongue (protrude it, retract it, move it side to side)

• **intrinsic muscles** of the tongue
- are skeletal muscles within the tongue
- allow the tongue to change shape during speech and swallowing

• the upper surface and sides of the tongue are covered with projections called **lingual papillae**, some of which contain microscopic **taste buds**

## Salivary Glands

• there are 3 pairs of salivary glands that secrete saliva into ducts that empty into the mouth; note their location in Fig. 22-7

1. **parotid glands**
   - each parotid duct opens into the oral cavity at the level of what tooth?

2. **sublingual glands**
   - their numerous ducts open where?

3. **submandibular glands**
   - the submandibular ducts open into the mouth where?

### Saliva

• list the numerous components of saliva:

· list functions of a continuous background level of saliva:

· list the functions of saliva produced when you eat:



Remember "flight-or fight"…does your mouth become more moist or dry when you are scared?

## Control of Salivary Secretions

· secretion of saliva is normally controlled by what?
- the parasympathetic nervous system stimulates the secretion of saliva
- the sympathetic ns inhibits the secretion of saliva

## The Teeth



◦ what is another word for mastication?

◦ the roots of teeth are located in sockets (**alveoli**) of the alveolar processes of the maxillae and mandible

◦ locate the following parts on Fig. 22-8:

· **gingiva** - gum

· **crown**
- define the crown of a tooth:

· **root** - the part of the tooth that occupies an alveolus

· **neck**
- define the neck of a tooth:

· **dentin** - a highly mineralized tissue that forms the bulk of a tooth

· **pulp cavity** - a central cavity, surrounded by dentin, that contains pulp (soft tissue with CT, blood vessels and nerves)

- **root canal** - the extension of the pulp cavity into the root of the tooth

- **apical foramen** - an opening at the proximal end of each root that allows blood vessels and nerves to supply the pulp cavity

- **periodontal ligament** -
  - anchors the tooth and acts as a shock absorber
  - define **periodontal ligament** *(✰ from the glossary in the back of the book)*:

- **cementum** - a calcified CT that covers the dentin of the root

- **enamel**
  - describe the location and composition of enamel:

## Types of Teeth

◦ describe the features and functions of the different **types of teeth**:

☺ **incisors**

☺ **cuspids** (canines)

☺ **premolars** (bicuspids)

☺ **molars**

## Dental Succession

◦ **2 sets of teeth in humans** (see Fig. 22-9):

☺ **deciduous (primary) teeth**

☺ **permanent (secondary) teeth**

### Mastication

- mastication mechanically digests food; teeth grind it and mix it with saliva
- the tongue manipulates food while chewing and forms a **bolus**, which is the soft rounded mass of food that gets swallowed

## 22.3 The pharynx...

- is a passageway for what?
- it is lined by mucous membrane; has skeletal muscles that are involved in swallowing

## 22.4 The esophagus...

- describe the esophagus:

- what is its primary function?

- name the opening in the diaphragm through which the esophagus passes:

### Histology of the Esophagus

- the circular muscle layers in the muscularis externa in the superior and inferior parts of the esophagus normally are contracted, functioning as sphincters; name these two sphincters:

### Histology of the Esophagus

- the mucosa of the esophagus consists of what type of epithelium?

### Swallowing

- what is another name for swallowing?
- there are three stages of swallowing (Fig. 22-11):

(1) **buccal stage**:
- begins with what?
- the tongue forces the bolus into where?
- is this stage voluntary or involuntary?

(2) **pharyngeal stage**:
- begins when the bolus passes into the oropharynx
- the larynx elevates and the epiglottis covers over the glottis, preventing the bolus from entering the larynx
- the uvula and soft palate do what?
- the bolus moves into the esophagus when the upper esophageal sphincter relaxes

(3) **esophageal stage**:

- when does it begin?

- what pushes the bolus in the esophagus toward the stomach?

- what sphincter relaxes for the bolus to enter the stomach?

# 22.5 The stomach...

- list the four major functions of the stomach:

- define **chyme**:

## Anatomy of the Stomach

- list the **four main regions** of the stomach and note their location in Fig. 22-12:

- the **pyloric sphincter** regulates the release of chyme into what?
- define **rugae:**

**Histology of the Stomach** (see Fig. 22-13)

- features of the **mucosa** of the stomach**:**
  - the stomach is lined by simple columnar epithelial cells that produce mucus
  - is the mucus alkaline or acidic?

  - what is the function of the alkaline mucous layer?

**gastric pits** = inward extensions of the surface epithelium; cells that line the gastric pits undergo cell division to continuously replenish the epithelium of the stomach

**gastric glands** – continuations of the gastric pits; lined by epithelial cells that secrete gastric juice:

☆ **parietal cells**

- what two substances do they secrete?

- what does intrinsic factor facilitate?

- the secretory activities of the parietal cells can keep the stomach contents at what pH?

- list the four important functions of the highly acidic contents of the stomach:

I know this is silly, but I remember that PARIETA**L** cells produce **HCl** because parietal ends in an "**L**"!

☆ **chief cells**

- what inactive enzyme do they secrete?

☆ cells that produce **hormones** (enteroendocrine cells) are also present:

- what do **G cells** produce?

  - what does gastrin stimulate?

▫ what type of muscle tissue do you think forms the muscularis externa of the stomach?

## Regulation of Gastric Activity

The production of acid and enzymes by the gastric mucosa can be controlled by hormones and the nervous system

***First, my summary of stimulation of the secretion of HCL by parietal cells in the stomach:***

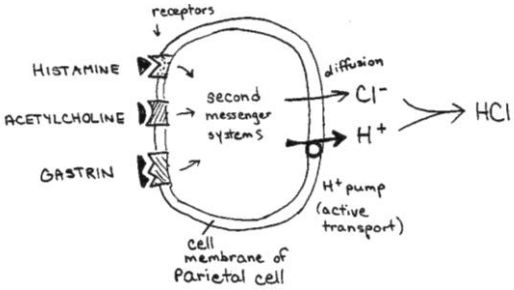


**1. Parasympathetic nerve impulses** stimulate the release of **acetylcholine** (ACh), which:

1. increases secretion of pepsinogen by chief cells
2. increases secretion of HCl by parietal cells
3. stimulates release of gastrin by endocrine cells (G cells)

**2. Gastrin** produced by G cells increases gastric secretion

**3. Histamine** produced by mast cells stimulates the parietal cells to secrete HCl
*(Note: the histamine receptors on the parietal cells are called H2 receptors, and are different from the H1 receptors of allergic reactions.)*

*THERE ARE THREE OVERLAPPING PHASES THAT OCCUR DURING DIGESTION:*



- ***CEPHALIC PHASE***
  - when does this phase begin?
  - during this phase, parasympathetic nerves stimulate the salivary glands to secrete saliva and gastric glands (via the vagus nerve) to secrete gastric juice
  - what is the purpose of the cephalic phase?

- ***GASTRIC PHASE***
  - when does this phase begin?
  - collectively, neural and hormonal mechanisms:
    - · increase in gastric secretion by the gastric glands
    - · increase motility of the stomach
    - · relax the pyloric sphincter to promote gastric emptying

- ***INTESTINAL PHASE***
  - when does this phase begin?
  - collectively, neural and hormonal mechanisms:
    - · decrease production of gastric juice by the gastric glands
    - · inhibit gastric motility and increases contraction of the pyloric sphincter to slow the emptying of chyme from the stomach
    - · stimulate secretion of pancreatic juice and release of bile from the gallbladder
    - · promote continued digestion of foods that are in the small intestine

## Digestion and Absorption in the Stomach

- mechanical digestion**:**
  - ∗ **mixing waves** are gentle rippling peristaltic waves that occur in the stomach; they macerate food, mix it with gastric secretions, and reduce it to semifluid material called chyme
  - ∗ each wave causes a small amount of chyme to be forced through the pyloric sphincter into the duodenum (first part of the small intestine) to cause **gastric emptying**, so that gradually the stomach empties chyme into the duodenum

- chemical digestion in the stomach
  - ∗ proteins begin to be broken down by the enzyme **pepsin** (formed from pepsinogen, which is inactive)
    - remember what cells of the gastric glands produce pepsinogen?

- absorption in the stomach
  - ∗ nutrients are not absorbed in the stomach for several reasons; read about the 4 reasons (p. 772
  - ∗ so, only a small amount absorption occurs in the stomach, such as water, ions alcohol and aspirin

If we are following the order of the organs that form the gastrointestinal tract, what organ would we study next? If you answered "small intestine" (or, more specifically, "duodenum"), that is correct! BUT, first we will study the pancreas and liver because they produce secretions that are carried to the duodenum by a duct system! The secretions of these organs, pancreatic juice and bile, function in the small intestine! We will also study the gallbladder, which stores bile from the liver.

## 22.6 The small intestine and associated glandular organs...

Duct System of the Liver, Gallbladder, and Pancreas

1.c. right and left hepatic ducts

2. common hepatic duct

3. cystic duct

4. common bile duct

5. opening of accessory pancreatic duct

6. pancreatic duct

7. hepatopancreatic ampulla

8. duodenal papilla

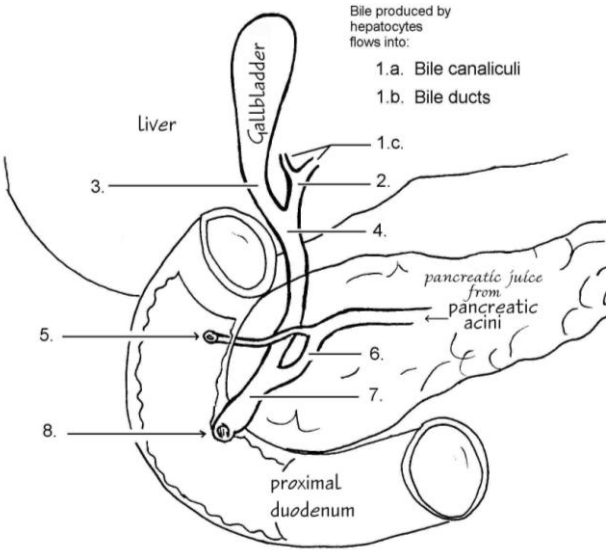


## The Pancreas (☆page 776)

- exocrine secretions are carried by the **pancreatic duct** and the **accessory pancreatic duct** from the pancreas to what organ (see Fig. 22-18)?

### Histological Organization

- the exocrine part of the pancreas is formed by clusters of epithelial cells called **pancreatic acini** that secrete **pancreatic juice** (see Fig. 22-18b and c)

- the name the endocrine tissue of the pancreas scattered among the acini:

- describe **pancreatic juice:**

  - the slightly alkaline secretion is important because the enzymes that function in the small intestine do not function in an acid environment

## Physiology of the Pancreas

- the cells of the pancreatic acini produce a variety of digestive enzymes that function in the small intestine

# The Liver (☆page 778)

- the liver is the second largest organ of the body and is located just inferior to the diaphragm

## Anatomy of the LIver

- subdivided into **lobes** that are visible grossly

- the liver receives blood from two sources
  1. **hepatic artery** – carries oxygenated blood
  2. **hepatic portal vein** - carries deoxygenated, nutrient-rich blood from systemic capillaries of digestive organs (stomach, intestines, etc) to sinusoids of the liver *(see Figs on page 653 and 662)*

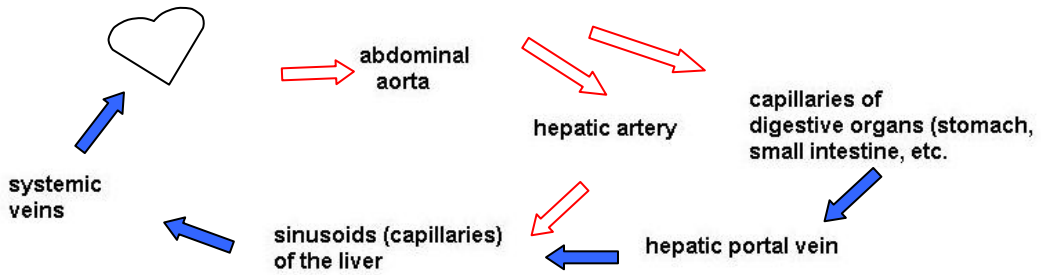


## Histological Organization of the Liver *(see Fig. 22-20)*

- each lobe of the liver is formed by numerous microscopic **lobules;** a lobule consists of:
  - ✓ special epithelial cells called **hepatocytes**
  - ✓ **sinusoids** that alternate with the rows of hepatocytes; they radiate from a **central vein** in the center of a lobule
  - ☆blood flows through the sinusoids from branches of the hepatic artery and hepatic portal vein
  - ✓**Kupffer cells** (macrophages of the liver) occupy the sinusoids
    - what do these phagocytic cells engulf?

- **portal areas** (**portal triads**) are located in the CT where three or more lobules meet
  - list the three structures that a portal area contains:
    (1)

    (2)

    (3)

**The Bile Duct System** *(☺ see Fig. 22-20b, Fig. 22-21, and page 11 of these notes)*:

· bile secreted by hepatocytes enters into **bile canaliculi**, which are tiny intercellular canals formed by the cell membranes of adjacent hepatocytes
→ bile canaliculi lead into **bile ducts** at the periphery of lobules
→ bile ducts merge and eventually form two ducts (the right and left hepatic ducts) that unite and exit the liver as the **common hepatic duct**
→ joins with the **cystic duct** from the gallbladder to form the **common bile duct**
→ leads into the **hepatopancreatic ampulla** (**duodenal ampulla**) that opens into the duodenum

**The Physiology of the Liver**

☆ read about the numerous functions of the liver on pages 780 to 782

*summary of functions of the liver:*

1. synthesizes heparin, albumin and other plasma proteins, coagulation factors
2. detoxifies toxic substances
3. has **Kupffer cells** that phagocytize worn/damaged rbc & wbc; bacteria, etc.
4. stores vitamins A, D, $B_{12}$; stores iron
5. processes newly absorbed nutrients
   e.g., converts glucose to glycogen; stores glycogen; converts glycogen to glucose
   e.g., converts carbohydrates and proteins to fats; e.g., synthesizes phospholipids
6. secretes **bile**

**The Functions of Bile**

- hepatocytes secrete a yellow to green liquid called **bile**
- features of bile:
  1. is alkaline (pH 7.6 to 8.6)
  2. contains water, ions, cholesterol, etc. (NO digestive enzymes!)
  3. contains **bile salts** *(which are the only substances in bile with a digestive function)*
     a. emulsify fat globules into fat droplets
     b. play a role in the absorption of long chain fatty acids, glycerol, cholesterol, and fat soluble vitamins
  4. contains **bile pigments,** such as bilirubin, which is a normal product of RBC destruction and is excreted into bile by hepatocytes

## The Gallbladder

- bile is carried by the duct system to the **gallbladder**
  - the gallbladder stores and concentrates bile until it is needed in the small intestine
  - when the small intestine is empty, a valve around the common duct closes and bile backs up into the cystic duct to the gallbladder for storage

## The Small Intestine *(☆ back to page 773!)*



- how long (in feet) is the small intestine?!
- list the <u>three segments</u> of the small intestine:

  - name the sphincter between the ileum and cecum of the large intestine:

**<u>Histology of the Small Intestine</u>** (see Fig. 22-17)

☆ *most chemical digestion and absorption of nutrients takes place in the small intestine, so there are special features of the small intestine that facilitate chemical digestion and absorption of nutrients: its great length, circular folds, villi, and microvilli*

- has permanent folds of the mucosa and submucosa called **<u>circular folds</u>** (plicae circulars) *(Fig. 24-16)*
  - these circular folds greatly increase surface area for chemical digestion and absorption
  - cause chyme to spiral slowly through the small intestine, to increase time for digestion and absorption
- **villi** (singular is "villus")
  - finger-like projections of the mucosa
  - formed by simple columnar epithelium with goblet cells covering a core of lamina propria
  - the lamina propria contains <u>blood capillaries</u> and a <u>lymphatic capillary</u> for absorption of nutrients
    - what is the lymphatic capillary called?
- simple columnar epithelial cells have **microvilli**
  - microvilli are fingerlike <u>projections of the cell membrane</u> of the epithelial cells

  - functions of microvilli:
    · they *contain digestive enzymes* produced by the epithelial cells and they increase surface area for chemical digestion
    · they also *increase surface area for absorption* of nutrients into the epithelial cells

  - **goblet cells** are also present in the epithelium
    - do you remember what goblet cells secrete?
- **intestinal glands** (crypts of Lieberkűhn) of the mucosa
  = deep crevices lined with glandular epithelial cells that secrete intestinal juice; these cells undergo cell division to replenish the epithelium!

  - what are **brush border enzymes**?

  - intestinal glands contain cells that secrete lysozymes, an enzyme that destroys some bacteria

  - also contain enteroendocrine cells that secrete hormones (gastrin; CCK, and GIP)
- what do **duodenal glands** in the submucosa of the duodenum produce *(page 775)*?
  - what are the functions of this mucus?

Is the pH of the chyme in the stomach acidic or alkaline? You may have been noticing that various secretions that are produced by the small intestine or that empty into the small intestine (bile and pancreatic juice) are ALKALINE. This is important to neutralize the acidic chyme that empties from the stomach into the small intestine to create a proper pH environment for the function of enzymes that act in the small intestine. They do not function in an acidic environment.

## Intestinal Secretions

- **intestinal juice**: contains water, mucus, and is slightly alkaline
- what are the functions of intestinal juice?

## Intestinal Movements

- **segmentation**
  - are localized mixing contractions that mix chyme with the digestive juices and bring the particles of food into contact with the mucosa for absorption
- **peristalsis** - weak, wave-like contractions that propel chyme toward the large intestine

## Chemical Digestion in the Small Intestine

- First, a little review of chemical digestion so far:… due to the actin of enzymes in saliva produced by salivary glands and enzymes produced in the stomach, chyme entering the small intestine contains partially digested carbohydrates, proteins and lipids

☆**chemical digestion in the small intestine** is a collective effort of:

- enzymes in pancreatic juice produced by the pancreas
- enzymes in intestinal juice
- enzymes on the microvilli produced by the epithelial cells in the small intestine

**A SUMMARY OF THE END PRODUCTS OF CHEMICAL DIGESTION:**

carbohydrates → monosaccharides
proteins → amino acids and peptides
lipids → fatty acids and monoglycerides
DNA and RNA → sugars and nucleotides

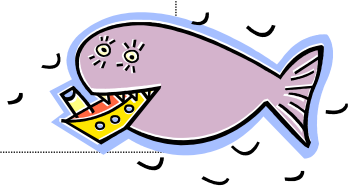

## Absorption in the Small Intestine

- the nutrients listed in the box above that are the end products of digestion are then absorbed
- **absorption** = passage of digested nutrients from the lumen of the gastrointestinal tract into the blood or lymph
  - 90% of absorption of nutrients takes place in the small intestine
  - 10% takes place in the stomach and large intestine

Here is a **summary of absorption**:

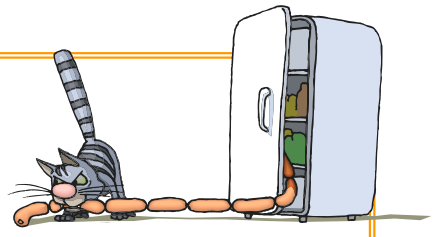

lumen of the small intestine → absorptive epithelial cells → underlying lamina propria

→ monosaccharides, amino acids, short-chain fatty acids, water and ions, water-soluble vitamins, etc. → BLOOD CAPILLARIES → to liver via hepatic portal vein

→ ✯ long-chain fatty acids, monoglycerides, fat soluble vitamins and cholesterol, etc. → LACTEALS → to blood in subclavian vein via lymphatic vessels

✯ the long-chain fatty acids, monoglycerides, fat soluble vitamins, and cholesterol are surrounded by <u>bile salts</u> to form **<u>micelles</u>** to get close to the microvilli of the epithelial cells; then close to the cell membrane they are released and diffuse into the cell.

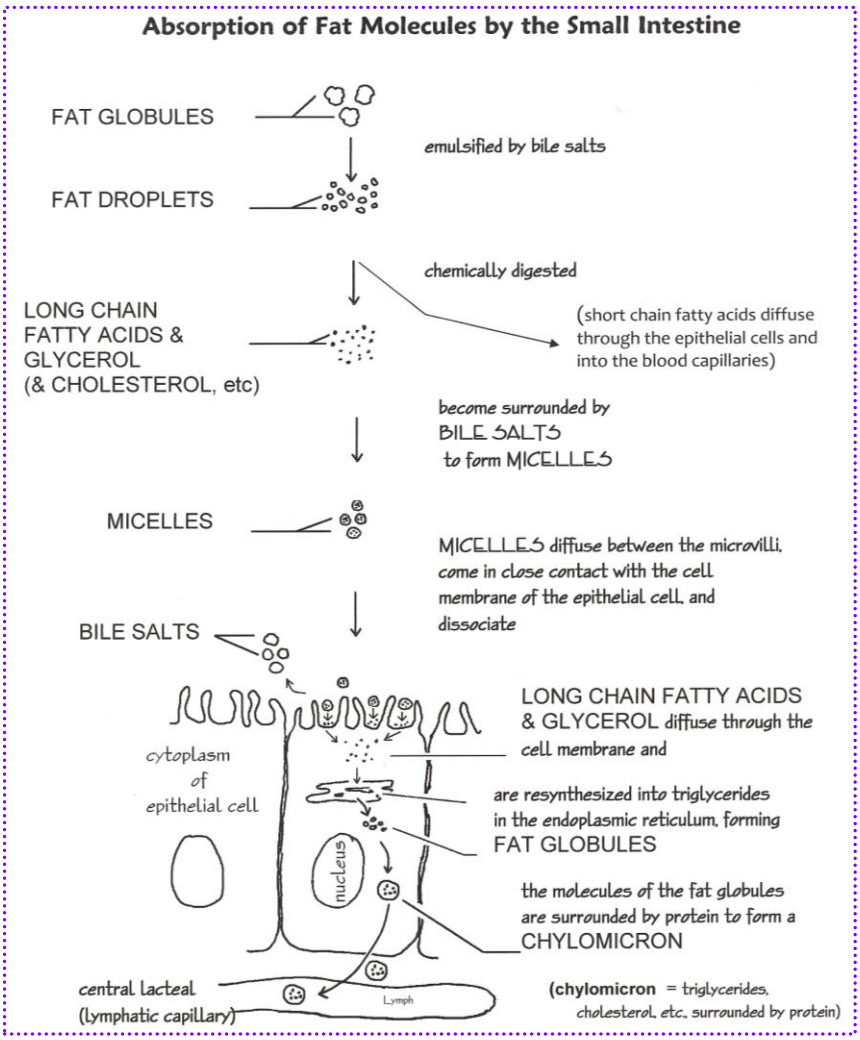

## 22.7 The large intestine... *(page 785!)*

- where does the large intestine begin and end?

- list the three major functions of the large intestine:

- ~5 ft. long, 2.5 in. in diameter
  *contrast its length and diameter with the small intestine:*
  ∗ which is longer?
  ∗ which is larger in diameter?
  ∗ why do you suppose the small intestine is called "small" and the large intestine is called "large"?

- list the **three parts of the large intestine** (and locate them in Fig. 22-23):

### THE CECUM

∗ the ileum leads into the pouchlike cecum; the **ileocecal sphincter** (ileocecal valve) controls the passage of chyme from the ileum into the cecum

∗ name the slender, hollow structure that is attached to the cecum:

### THE COLON

∗ what are the series of pouches called in the wall of the colon?

∗ what do haustra permit?

∗ the colon is gathered into haustra by muscle tone of three longitudinal bands of smooth muscle called what?

∗ list the <u>four parts of the colon</u> and note their locations in Fig. 22-23:

### THE RECTUM

∗ describe the **rectum**:

∗ what is the last portion of the rectum called?

∗ define **anus**:

∗ list the <u>two sphincters</u> of the anus and indicate the type of muscle tissue that forms each and whether they are under voluntary or involuntary control:

## Histology of the Large Intestine

- the simple columnar epithelium contains numerous goblet cells
- the epithelium forms **intestinal glands**, as in the small intestine, but there are not villi or circular folds
- does the mucosa of the large intestine produce enzymes?
- any digestion that occurs in the large intestine results from what?

## Physiology of the Large Intestine

- the last stage of digestion occurs in the colon through the activity of bacteria in the colon: bacteria ferment any remaining carbohydrates and release $H^+$ ions, $CO_2$ and methane gas; bacteria convert remaining protein to amino acid; breakdown amino acids; convert bilirubin to stercobilin, which gives feces their brown color; produce vitamins B and K

### Absorption in the Large Intestine

- absorption: some water, electrolytes, some vitamins (B and K)
- as the chyme remains in the large intestine for 3 to 10 hours, water absorption converts it to a solid or semisolid form called feces
  - ∗ what do feces consist of?

### Movements of the Large Intestine

- **peristalsis**
  - slower than in other parts of the GI tract
- segmentation movements in the large intestine that mix the contents of the haustra are called what?

- **mass peristalsis**
  - a strong peristaltic wave that begins in the transverse colon and drives the feces in the colon into the rectum

☺ **The Defecation Reflex**

mass peristalsis, a strong peristaltic wave that begins in the transverse colon, drives the feces in the colon into the rectum → distention of the rectum → initiates the urge to defecate → internal sphincter of the anus relaxes involuntarily; external sphincter of the anus relaxes voluntarily → defecation ☺

*THE END!*